

# Comorbid Panic Disorder and Chiari I Malformation: A Case Report

Murat Kuloğlu\*, Ali Çayköylü\*, Okan Ekinci\*\*, Yakup Albayrak\*\*, Orhan Deniz \*\*\*

\* Assoc. Prof., Atatürk Education and Research Hospital, Department of Psychiatry, Ankara, Turkey

\*\* M.D, Atatürk Education and Research Hospital, Department of Psychiatry, Ankara, Turkey

\*\*\* Prof., Atatürk Education and Research Hospital, Department of Neurology, Ankara, Turkey

Corresponding Author a. Atatürk Eğitim ve Araştırma Hastanesi Psikiyatri Kliniği 06520 Bilkent/Ankara, Turkey

Tel.: +90 312 2912525

Fax: +90 312 2912705

E-mail address: kuloglum@yahoo.com

## ABSTRACT

Chiari I malformation is a congenital hindbrain anomaly characterized by downward displacement of the cerebellar tonsils through the foramen magnum, commonly presents in patients with headache or symptoms of dysfunction of the cerebellum, brainstem, and cervical spinal cord. To our knowledge, there is a limited literature about any anxiety disorder in association with this anomaly. We describe a patient who firstly presented with panic symptoms and who later proved to have Chiari I malformation. The patient had no surgical intervention for this malformation and had a relative clinical improvement of her anxiety symptoms after psychotropic medication. This case highlights the importance of searching for a lesion that might otherwise go undetected in light of normal physical and neurological examinations and laboratory findings. Also, it demonstrates a rare comorbidity of Chiari I malformation and panic disorder.

**Keywords:** Chiari malformation, panic disorder, comorbidity, brainstem

## ÖZET

### Panik Bozukluk ve Chiari I Malformasyonu Birlikteliği: Bir Vak'a Sunumu

Chiari I malformasyonu sıklıkla baş ağrısı veya serebellum, beyin sapı ve medulla spinalisin servikal bölümünün disfonksiyonuna ilişkin semptomlar ile tanınan ve serebellar tonsillerin foramen magnumdan aşağıya doğru yer değiştirmesi ile karakterize bir konjenital beyin anomalisidir. Bildiğimiz kadarıyla bu anomali ile bir anksiyete bozukluğu arasındaki ilişkiyi târif eden sınırlı literatür bilgisi mevcuttur. Biz, ilk safhada panik semptomları ile başvuran daha sonra Chiari I malformasyonu olduğu tespit edilen bir hasta rapor ediyoruz. Vak'aya malformasyonu için cerrahi tedavi uygulanmamıştır. Psikotrop tedavi sonrası anksiyete semptomlarında izafi klinik düzelme görülmüştür. Bu vak'a fizik ve nörolojik muayene ile laboratuvar bulgularının normal olmasından dolayı gözden kaçmış bir lezyonu araştırmanın önemine vurgu yapmaktadır. Ayrıca panik bozukluğu ile Chiari I malformasyonu arasında sık olmayan bir komorbiditeyi göstermektedir.

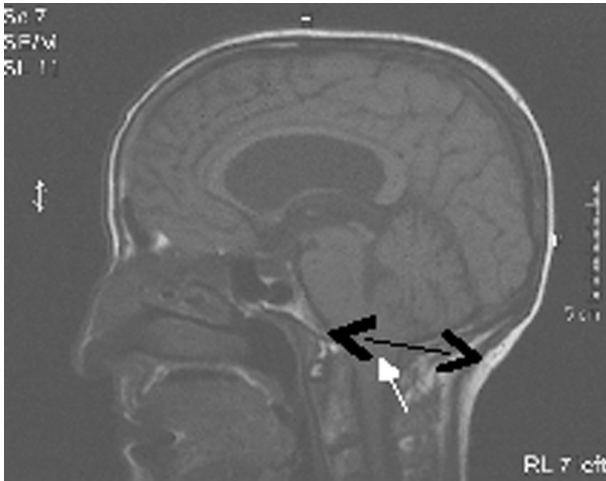
**Anahtar Kelimeler:** Chiari malformasyonu, panik bozukluğu, komorbidite, beyinsapı

## INTRODUCTION

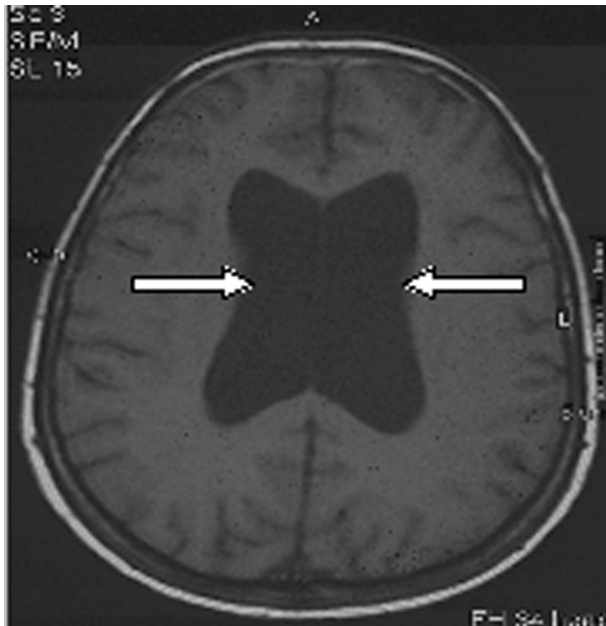
Chiari malformation is a disorder of embryologic development. Chiari I is a congenital malformation characterized by herniation of cerebellar tonsils through the foramen magnum. Chiari II malformation consists of herniation of not only the tonsils, but also all of the contents of the posterior fossa into the foramen magnum. Chiari III and IV malformations are ra-

re (Susman et al. 1989, Nash et al. 2002).

To date, there are three cases have been reported of an anxiety disorder in association with this anomaly (Chisholm et al. 1993, Iwabuchi et al. 1985, Cayköylü et al. 2008). We report a case of female patient with panic disorder who later proved to have Chiari I malformation and had relative clinical improvement after antidepressant treatment without surgery.



**Figure 1:** MRI of patient shows cerebellar tonsil [white arrow] displaced 9 mm below foramen magnum [black arrow] and displacement of brainstem.



**Figure 2:** Cranial MRI image in a horizontal plane, showing hydrocephalus with dilated lateral ventricles [arrows].

### CASE REPORT

Mrs. H was 49-year-old, admitted to our outpatient clinic. Upon examination, she was found to suffer from recurrent unexpected panic attacks and agoraphobia. She has also worried about having a heart attack and going crazy. At the age of 48, she developed spontaneous panic attacks, which were characterized by the acute onset of unprovoked and intense anxiety accompani-

ed by rapid breathing, palpitations, and sweating, trembling, fear of dying, hot flashes and feeling of imminent death. The attacks occurred in intervals of several days at different times of the day. None of the attacks, which lasted from 5 to 20 minutes, was accompanied by loss of consciousness, motor phenomena, amnesia, or any other epileptic symptoms. The patient was extremely concerned about having these attacks and said that it caused major changes in her behavior and daily life. There was no personal history of substance misuse or previous psychiatric disorders, and no family history of mental illness. She was diagnosed with panic disorder with agoraphobia based on the diagnostic criteria of the Diagnostic and Statistical Manual of Mental Disorders, Fourth edition - Text Revision [DSM-IV-TR] (American Psychiatric Association, 2000).

The patient's physical, neurological and laboratory examinations showed normal findings and an electroencephalograph [EEG] revealed no abnormality. Also, she has been suffered from vertigo and headache. Subsequently, brain magnetic resonance imaging [MRI] was performed and revealed the presence of triventricular hydrocephaly, displacement of brainstem and that the cerebellar tonsils herniated 9 mm into the foramen magnum [as seen in Figs. 1 and 2]. After consultation with the Department of Neurosurgery, a diagnosis of Chiari I malformation was established, and the neurosurgery department planned a surgery intervention include decompression and shunt procedure. However, the patient did not approve surgery intervention after she was informed about surgery procedure and risks by the neurosurgery department. They subsequently proposed an outpatient follow-up without surgery.

In the past one year, although she had been treated sequentially with various anxiolytic and antidepressant drugs, she had only relative clinical improvement. When the patient was admitted to our outpatient clinic, he had been off of medication for about three months. During this period, she had been applied to emergency medical department for palpitation and chest pain, where she was often given anxiolytic drugs and then discharged. At admission, sertraline was started po at a dose of 25 mg/day and gradually increased to 50 mg/day. The severity of her panic symptoms was assessed by using the Panic Disorder Severity Scale [PDSS] (Shear et al. 1997). Initially her PDSS score was 24. Total scores on the PDSS in the second, fourth and sixth weeks were 23, 16 and 14 respectively. There was a relative clinical improvement of her panic symptoms at the end of sixth week after sertraline was increased to 50 mg/day. Subsequently

we planned follow-up outpatient care, including both psychiatric and neurosurgical appointments.

## DISCUSSION

Panic disorder is characterized by the presence of recurrent, unexpected panic attacks followed by at least one month of persistent concern about having another attack. Panic attacks generally occur during daily activities, suddenly and without any apparent reason. They are a common feature of panic disorder and can also be induced by different cerebral diseases (Wiest et al. 2006, Thompson et al. 2000).

It is known that Chiari malformation can lead to compression of the lower brainstem (Nash et al. 2002). Moreover, the malformation may result in neuronal impairment of the brainstem, upper spinal cord and cranial nerves (Botelho et al. 2005). Neurocircuitry models of panic disorder have hypothesized that the panic attack itself stems from loci in the brainstem (Protopopescu et al. 2006). In the case of our patient, it would be conceivable that the compression of brainstem and disruption of its connections could have made the patient susceptible to panic attacks. On the other hand, at this time, the association between the Chiari I malformation and panic disorder remains unclear. It is possible that, in this patient, both diseases are separate unrelated pathological events.

A substantial number of patients with panic disorder and agoraphobia may remain symptomatic after standard treatment. It is known that there are some factors, such as psychiatric and medical comorbid disorders, psychosocial complications and physiologic provocations, which can cause treatment difficulties in panic disorder (Bandelow and R  ther 2004, Rosenbaum 1997). In the present case, although appropriate antidepressant treatment (in adequate dose and time) was administered, there was a partial clinical improvement in her panic symptoms. Moreover, the patient had no alternative factor (such as other medical disease, psychosocial stress factors) that contributes to inadequate treatment response. Therefore, it is possible to suggest that comorbid Chiari malformation may be a cause of patient's inadequate treatment response.

The present case also presented with hydrocephalus. It's well known that the tonsillar herniation may be secondary to hydrocephalus (Samii et al. 1999). However, Chiari malformations cause obstruction to cerebrospinal fluid flow in the posterior fossa and foramen magnum that elevates cranial pressure and this can cause hydrocephaly. It can damage neural tissue by ischemic and mechanical forces (Williams 2008). It

is possible that in this case an alteration in CSF circulation had functionally damaged the cortical subcortical circuits. This may be another factor that contributes to emergence panic attacks and also probably cause difficulty to treatment.

## CONCLUSION

With this report we want to emphasize that selecting the appropriate treatment for such patients can be confounded by factors such as comorbid disorders both psychiatric and medical. The clinicians must assess these factors before an optimal therapeutic strategy can be designed.

## REFERENCES

- American Psychiatric Association (2000) Diagnostic and Statistical Manual of Mental Disorders. 4th edition, Text Revision, Washington, DC.
- Bandelow B, R  ther E (2004) Treatment-resistant panic disorder. *CNS Spectr*; 9: 725-739.
- Botelho RV, Bittencourt LR, Rotta JM, Tufik S (2005) Adult Chiari malformation and sleep apnoea. *Neurosurg Rev*; 28: 169-176.
- Caykoylu A, Ekinci O, Albayrak Y, Kuloglu M, Deniz O (2008) Arnold-Chiari I malformation association with generalized anxiety disorder: A case report. *Prog Neuropsychopharmacol Biol Psychiatry*; 32: 1613-1614.
- Chisholm BT, Velamoor R, Chandarana PC, Cochrane DK (1993) Anxiety disorder in a case of Arnold-Chiari malformation. *J Psychiatry Neurosci*; 18: 67-68.
- Iwabuchi K, Miyauchi T, Kyuuma Y, Hosaka H, Kunimi Y, Yagishita S (1985) A sudden death in a case of Arnold-Chiari malformation (type I) with sleep apnea. *No To Shinkei*; 37: 575-581.
- Nash J, Cheng JS, Meyer GA, Remler BF (2002) Chiari type I malformation: overview of diagnosis and treatment. *WMJ*; 101: 35-40.
- Protopopescu X, Pan H, Tuescher O, Cloitre M, Goldstein M, Engelen A, et al (2006) Increased brainstem volume in panic disorder: a voxel-based morphometric study. *Neuroreport*; 17: 361-363.
- Rosenbaum JF (1997) Treatment-resistant panic disorder. *J Clin Psychiatry*; 58: 61-64.
- Samii C, M  bius E, Weber W, Heienbrok HW, Berlit P (1999) Pseudo Chiari type I malformation secondary to cerebrospinal fluid leakage. *J Neurol*; 246: 162-164.
- Shear MK, Brown TA, Barlow DH, Money R, Sholomskas DE, Woods SW, et al (1997) Multicenter collaborative Panic Disorder Severity Scale. *Am J Psychiatry*; 154: 1571-1575.
- Susman J, Jones C, Wheatley D (1989) Arnold-Chiari malformation: a diagnostic challenge. *Am Fam Physician*; 39: 207-211.
- Thompson SA, Duncan JS, Smith SJ (2000) Partial seizures presenting as panic attacks. *BMJ*; 321: 1002-1003.
- Wiest G, Lehner-Baumgartner E, Baumgartner C (2006) Panic attacks in an individual with bilateral selective lesions of the amygdala. *Arch Neurol*; 63: 1798-1801.
- Williams HA (2008) unifying hypothesis for hydrocephalus, Chiari malformation, syringomyelia, anencephaly and spina bifida. *Cerebrospinal Fluid Res*; 5: 7.